RESEARCH FOR THE
UPPER CERVICAL RESEARCH FOUNDATION (UCRF)

Changes in Cerebral Blood Flow Patterns and Velocities of Migraine Subjects Following an Atlas Correction

Utilization of Phase Contrast Magnetic Resonance Imaging to measure Cerebral Hemodynamic Changes
Before and After a NUCCA Atlas Correction - A Case Series

Results of a case study describing a subject diagnosed with migraine headache (without aura) reveal compelling results obtained with Phase Contrast Magnetic Resonance Imaging Angiography (PC MR). The subjects were evaluated using the protocol of the National Upper Cervical Chiropractic Association (NUCCA) to determine the presence of an Atlas misalignment. After Atlas correction, a follow up PC MR Study demonstrated changes in cerebral venous outflow. A change in vessel outflow pattern from a jugular to the paravertebral plexus route was discerned. Venous flow rate and vessel pulsatility decreased as well as cerebrospinal flow rate across the Atlas (C-1) vertebra. Most significantly, the imaging procedure measured a distinct decrease in intracranial compliance (the resilient adaptive capacity of the brain). The subjects obtained relief from migraine headache pain consistent to maintenance of the Atlas correction by the end of thirty days. The PC MR exam continued to show improvement of the hemodynamic parameters measured over the 16-week study period consistent to maintenance of Atlas alignment.

These results coupled with previously documented normalization of blood pressure in a randomized double blind study indicate a casual physiologic and measureable effect occurs after the correction of an Atlas misalignment. Further investigation will evaluate the physiologic mechanism with the misalignment and after its correction. The potential resulting from this study in alleviating migraine pain resultant to an Atlas correction may provide important evidence of NUCCA as a viable alternative to usual and customary treatment. This case series, imaging twelve subjects diagnosed with migraine headache by Dr. Werner Becker, a Neurologist at the CHAMP clinic at the Foothills Hospital, is important to demonstrate consistency in the improved cerebral hemodynamic effects after a NUCCA correction that were observed in the previous study.

Specific Aims

1) Document the effect of Atlas correction on Cerebral Venous and CSF outflow patterns and velocities, with decreased intracranial compliance, as measured by PC MRA in a case series study of ten migraine (without aura) neurologist diagnosed subjects.

2) Observe similarities and differences in a subject's subjective response to correction and ablation of migraine symptoms, headache pain, in relation to documented changes in PC MRA.

3) Demonstrate PC MR measured results and velocities are reproducible, sustained, and consistent over time, after an Atlas correction.

This study is significant in bringing a new imaging technology into Canada while offering another research facility to conduct productive investigation in determining a physiologic mechanism underlying the Atlas misalignment and its correction. This case series here in Calgary, with twelve migraine subjects that will be monitored by PC-MR measurements of the cerebral circulatory in response to the Atlas correction, has the potential to reveal much new information of an underlying physiologic mechanism.

Imaging Study Subject Visit Procedure

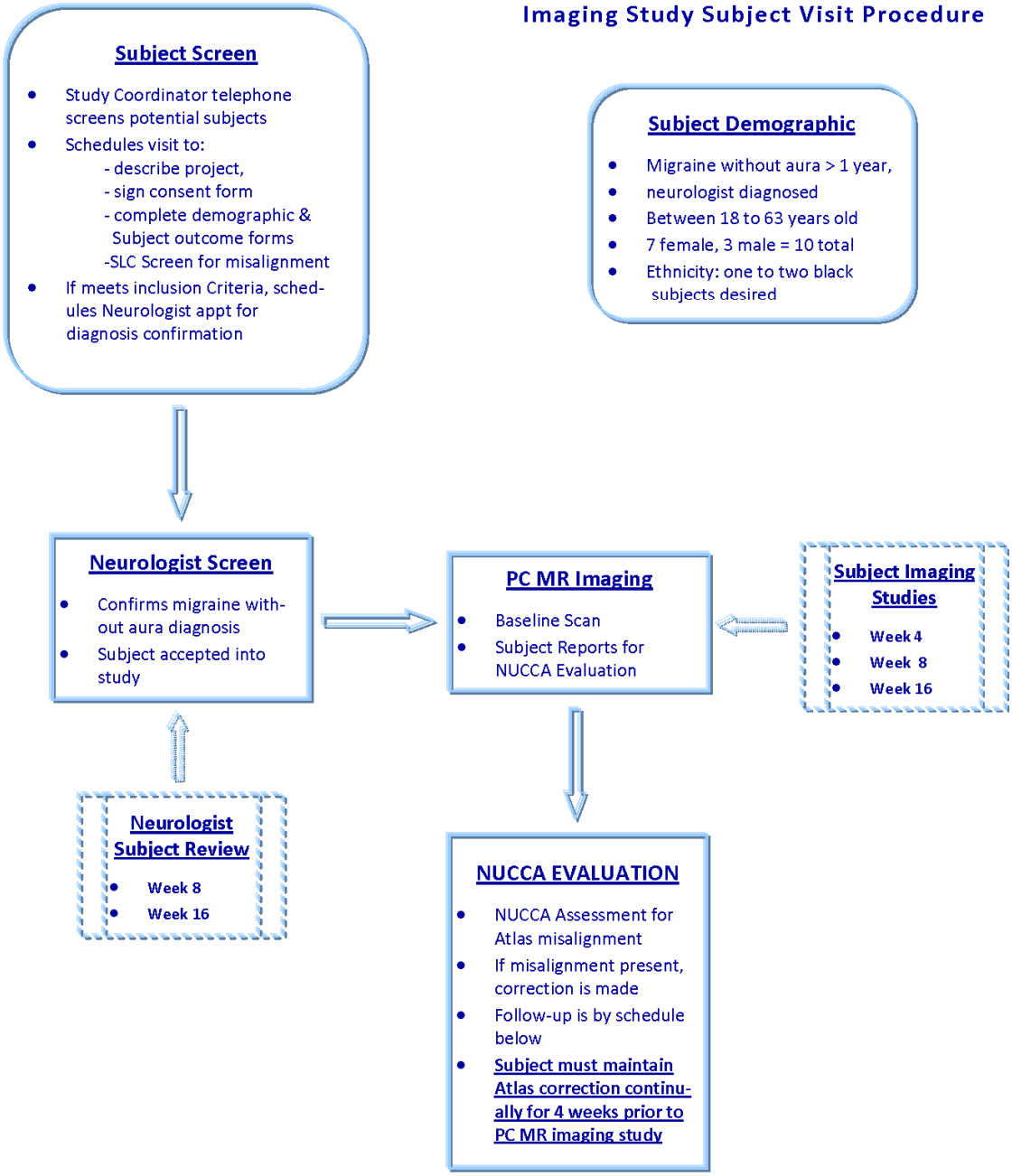

Subject Visits	Baseline	W 1	W 2	W 3	W 4	W 5	W 6	W 7	W 8	W 9	W 10	W 11	W 12	W 13	W 14	W 15	W 16
NUCCA	X	X	X	X	X		X		X			X			X		X
Neurologist	X								X								X
PC MR	# 1				# 2				# 3								# 4