ELSEVIER

Brachytherapy 10 (2011) 121−127

BRACHYTHERAPY

The use of adjuvant high-dose-rate breast brachytherapy in patients with collagen vascular disease: A collaborative experience

Anthony E. Dragun[1,*], Jennifer L. Harper[2], S. Eric Olyejar[3], Raul G. Zunzunegui[4], David E. Wazer[5]

[1]*Department of Radiation Oncology, University of Louisville School of Medicine, Louisville, KY*
[2]*Department of Radiation Oncology, Medical University of South Carolina, Charleston, SC*
[3]*Department of Radiation Oncology, Ironwood Cancer and Research Centers, Mesa, AZ*
[4]*Department of Surgery, Tanner Medical Center, Carrollton, GA*
[5]*Department of Radiation Oncology, Brown University School of Medicine, Providence, RI*

ABSTRACT

PURPOSE: To analyze toxicity and cosmesis in patients with collagen vascular disease (CVD) treated with accelerated partial breast irradiation (APBI) via high-dose-rate (HDR) brachytherapy.
METHODS AND MATERIALS: This is a pooled analysis of patients with early stage and *in situ* breast cancer with CVD treated with adjuvant multicatheter or balloon brachytherapy. Physicians at multiple institutions were asked to review their experience and report data regarding toxicity and cosmesis in patients with CVD. All patients fit American Society of Breast Surgeons recommendations for APBI and were treated with HDR brachytherapy with ≥3 months followup.
RESULTS: Nine cases from five institutions are the subject of this analysis. The median patient age was 54 years and median followup was 31 months. All patients had documented history and active signs/symptoms of rheumatoid arthritis, systemic lupus erythematosis, psoriatic arthritis, or scleroderma. All patients had received medical therapy for CVD in the past, and 78% were under active treatment at the time of brachytherapy. All the patients were treated with multicatheter or balloon (MammoSite [Hologic, Inc., Marlboro, MA], MammoSite ML [Hologic, Inc., Marlboro, MA], or Contura [Senorx, Irvine, CA]) brachytherapy with a median volume of 45.5 cc and a median skin distance of 7.5 mm. Acute toxicity included Grade 1 skin erythema (5) and catheter-site wound dehiscence (1). Late toxicity included seroma (5), induration (5), pain (2), telangectasia (2), and superficial infection (1). Cosmesis was excellent or good for all the patients.
CONCLUSIONS: Women with CVD have a toxicity and cosmesis profile consistent with other APBI series. Although confirmatory data is needed, it may not be necessary to exclude these patients from clinical trials of APBI. © 2011 American Brachytherapy Society. Published by Elsevier Inc. All rights reserved.

Keywords: Breast cancer; Collagen vascular disease; High-dose-rate brachytherapy; Accelerated partial breast irradiation

Introduction

Collagen vascular disease (CVD), such as rheumatoid arthritis (RA), systemic lupus erythematosus (SLE), scleroderma, dermatomyositis, and others, are diseases that most affect middle-aged women in age groups that coincidentally correlate with the incidence of breast cancer (1). For women diagnosed with *in situ* or early stage breast cancer, a well-established treatment paradigm is breast conservation therapy (BCT), which traditionally involves whole-breast radiation therapy after partial mastectomy. Although the oft-cited evidence is mostly retrospective or anecdotal, CVD is considered by many clinicians to pose an absolute or relative contraindication for BCT because of risks of increased acute and late toxicity to the skin and subcutaneous tissues resulting from whole-breast radiation therapy (2−5). Over the last 10−15 years, efforts

Received 23 March 2010; received in revised form 6 May 2010; accepted 7 May 2010.

Conflict of interest statement: There has been no assistance with manuscript preparation or data collection. There are no financial support or conflict of interest issues to disclose.

* Corresponding author. Department of Radiation Oncology, University of Louisville, James Graham Brown Cancer Center, 529 South Jackson Street, Louisville, KY 40202. Tel.: +1-502-561-2710; fax: +1-502-561-2709.

E-mail address: aedrag01@louisville.edu (A.E. Dragun).

1538-4721/$ - see front matter © 2011 American Brachytherapy Society. Published by Elsevier Inc. All rights reserved.
doi:10.1016/j.brachy.2010.05.001

have been undertaken to improve the quantity and quality of the medical literature relating to the use of radiotherapy in patients with CVD, with large institutional reports and reviews on this subject (1). Nevertheless, women with both breast cancer and CVD are a heterogeneous group, and the development of consistent and optimal treatment paradigms for such patients remains challenging in the era of multidisciplinary breast cancer therapy.

Adjuvant breast brachytherapy is a form of accelerated partial breast irradiation (APBI), which targets only the tissue immediately adjacent to the lumpectomy cavity after breast conserving surgery. It is a novel and increasingly popular approach to adjuvant radiation therapy in properly selected patients undergoing BCT (6). Multicatheter brachytherapy and balloon brachytherapy are the techniques for which there exists the largest amount of published clinical data, with multiple studies showing a low acute toxicity profile by virtue of its ability to limit the dose to the skin (7−10). The low volume of skin dose achieved with breast brachytherapy may be particularly advantageous for those patients with CVD who choose to undergo BCT. However, because of the controversies that exist in the medical literature regarding the treatment of patients with CVD with radiotherapy, these patients have been excluded from participation in major protocols evaluating APBI, such as NSABP B-39/RTOG 0413.

Throughout the country, properly selected patients with CVD have, in close consultation with their treating physicians, have been treated using breast brachytherapy outside of current national protocols. The hypothesis is that APBIs ability to limit normal tissue dose may be a particular utility in this population that is theorectically at a higher risk of radiation-induced skin complications. In contrast, the large radiation fraction sizes incorporated in APBI, combined with the poorly understood mechanisms underlying the CVD−radiotherapy relationship may result in a higher than expected rate of acute and late toxicity. Additionally, patients with autoimmune disorders such as CVD may be at a higher risk than the general populations for complications related to invasive procedures (such as brachytherapy catheter placement) such as infection and impaired wound healing. The purpose of this study is for physicians at multiple institutions across the United States who perform a high volume of breast brachytherapy procedures, and who have treated patients with CVD, to pool their experiences in a restrospective review for the purpose of providing evidence-based guidance for the challenging treatment decision-making process that confront these patients and their treating physicians.

Methods and materials

The initial coordination of this study and institutional review board approval took place at the University of Louisville's James Graham Brown Cancer Center. Forty physicians across North American who are known to treat a high volume of breast brachytherapy patients were contacted and invited to submit their experience with the treatment of patients with CVD with breast brachytherapy. Each potential investigator was provided with a standardized data collection sheet detailing patient demographics, CVD history, brachytherapy treatment specifics, and acute and late toxicity ratings. Twenty-one physicians responded to the survey requests and five physicians indicated both an experience with treating patients with CVD with breast brachytherapy and an interest in participating in the collaborative study. Participating physicians were encouraged to comply with their individual institutional review board standards for the collection and submission of the study data.

Patients were eligible for this analysis if they had a documented history of CVD at the time of their breast cancer diagnosis and if they were treated with definitive breast brachytherapy as adjuvant treatment for early stage breast cancer or ductal carcinoma *in situ* (DCIS). Only patients who fit criteria for APBI as set forth by the American Society of Breast Surgeons and/or the American Brachytherapy Society were eligible for this analysis. The American Society for Therapeutic Radiation Oncology consensus guidelines for APBI were not yet published at the time of the initiation of the study (6). Patients must have had a minimum of 3 months of followup since their completion of their brachytherapy. All techniques of ^{192}Ir−based high-dose-rate (HDR) brachytherapy techniques were eligible (multicatheter brachytherapy, single-catheter balloon brachytherapy, multiple-catheter balloon brachytherapy). Patients treated with low-dose-rate brachytherapy, electronic brachytherapy techniques, or APBI using three-dimensional conformal external beam radiotherapy were not eligible to be included in this analysis.

Physicians who agreed to participate completed and submitted one data collection sheet for each patient that fit the aforementioned selection criteria. All available information from the patient's medical record (Surgical Oncology, Medical Oncology, and Radiation Oncology records) were retrospectively reviewed to provide the most accurate information on each submitted patient data sheet. Data submitted to the study coordinator contained no protected health information, but did contain a "patient code" determined by the submitting physician to aid with any questions or future data collection and/or updates by the principal investigator. Physicians who have incorporated "before and after" photographs of the treatment of patients to document cosmetic outcome as part of their usual and customary practice were encouraged to also submit these along with data collection sheets. Photographs for documentation were prohibited from containing any patient identifying features and were labeled according to the time course from completion of radiation therapy.

Data on each CVD patient were to include the overall history and type of CVD, physical signs and reported

symptoms related to CVD at the time of breast cancer diagnosis and treatment, and the details regarding the time course and treatment for CVD. With regard to breast cancer treatment, data were collected on the type and related dosimetry of breast brachytherapy. Data were also collected on systemic therapy including the use of hormonal therapy and cytotoxic chemotherapy. Data regarding toxicity were divided into two categories: that which occurred in the acute phase of treatment and that which was considered as late toxicity. On treatment toxicity was defined of that which occurred. Acute toxicity was defined as occurring from the time brachytherapy catheters were in place through 8 weeks of completion of brachytherapy. Late toxicity was defined as occurring after that period of time. Cosmetic outcome (Harvard scale) was defined by the treating physician and submitted accordingly. Physicians were also given the discretion to provide any additional information specific to the patient's case that may have been useful in the final analysis.

Results

A total of (9) patient cases from five submitting physicians are the subject of this analysis. The median age for the cohort was 54 years, and the median followup time from completion of brachytherapy was 31 months. All other information regarding primary disease stage and histology is summarized in Table 1. All patients were lymph node negative and had DCIS or infiltrating ductal or lobular carcinoma of the breast. The individual history of CVD varied widely among treated patients. Specifics of CVD, correlating signs and symptoms, and treatment are detailed in Table 2. Most of the patients had RA (4) followed by SLE (2), psoriatic arthritis (2), and scleroderma (1). All patients had clinical signs and/or symptoms of their CVD at the time of their diagnosis and treatment for breast cancer. The overwhelming majority of patients were under active treatment for their CVD at the time of initiation of brachytherapy (77.8%) and/or had undergone the treatment for their CVD within the past 12 months (88.9%).

Table 1
Patient and disease characteristics

Characteristic	Number	Percent
Total no. of patients	9	100
Age (yr)		
Median	54	
Range	47−74	
Followup (mo)		
Median	31	
Range	3−56	
T-Stage		
is	2	22
1a	0	0
1b	5	56
1c	2	22
N-Stage		
0	9	100
1	0	0
Histology		
DCIS	2	22
IDC	6	67
ILC	1	11

DCIS = ductal carcinoma *in situ*; IDC = infiltrating ductal carcinoma; ILC = infiltrating lobular carcinoma.

In terms of systemic therapy, all patients in this study were treated with adjuvant hormonal therapy after the completion of brachytherapy. One patient received adjuvant cytotoxic chemotherapy after the completion of brachytherapy. Specifics regarding the type of brachytherapy are detailed in Table 3. Most of the patients (8) received some form of balloon brachytherapy, with 5 undergoing MammoSite (Hologic, Inc., Marlboro, MA) single-catheter balloon brachytherapy, and 3 patients undergoing multicatheter balloon brachytherapy using Contura (Senorx, Irvine, CA) or MammoSite ML (Hologic, Inc., Marlboro, MA). One patient underwent traditional multicatheter brachytherapy. For patients treated with balloon brachytherapy, the median balloon volume was 45.5 cc and the median balloon-to-skin distance was 7.5 mm. In terms of dose, most of the patients (8) received a total dose of 34 Gy in 10 fractions and 1 patient received a total dose of 32 Gy in 14 fractions.

Acute toxicity was judged to be minor in most instances (Fig. 1), with most of the toxicity related to radiation dermatitis, which was judged to be mild in all five cases in which it occurred (Fig. 2). Other acute side effects reported were minor and included pain and delayed wound healing. Late side effects mainly related to the development of posttreatment seroma and induration (Fig. 3). Of the 5 patients who experienced the development of a posttreatment seroma, 2 were described only on radiographic surveillance, 2 were palpable, and 1 required surgical drainage because of pain and discomfort. Five patients experienced fibrosis or induration and all were described as a mild or moderate. One patient had symptoms consistent with a posttherapy superficial infection treated with oral antibiotics, and moderate to severe pain, which was eventually controlled with a combination of a nonsteroidal anti-inflammatory drugs, steroid therapy, and neurolytics. Late development of telangectasias was described in 2 patients with significant and prominent telangectasias documented in 1 patient. At the time of last update of this data, there were no described severe infections, skin ulceration, or radiation necrosis requiring surgical intervention. Physician-assessed cosmetic outcome was described as excellent in 6 patients and good in 3 patients. No patients were described as having a fair or poor cosmetic outcome.

Discussion

The use of radiotherapy in patients with CVD has been a subject of controversy and debate for decades. Not long

Table 2
Individual collagen vascular disease-specific characteristics, stigmata, and past treatment of patients included in this analysis

Patient reference number	Treating institution	Age (yr) at diagnosis of breast cancer	Followup since completion of brachytherapy (mo)	Type of CVD	Clinical signs and symptoms of CVD	Active treatment for CVD at time of brachytherapy	Treatment for CVD within previous 12 (mo)	Type of therapy for CVD
1	UL	53	7	RA	Joint swelling	No	No	Gold, Plaquanil, Prednisone
2	UL	74	4	RA	Joint swelling	Yes	Yes	Methotrexate
3	UL	54	3	RA	Joint swelling	Yes	Yes	Enbrel, Methotrexate
4	MUSC	47	34	SLE	Diffuse joint and skin, pulmonary and renal involvement	Yes	Yes	Cellcept/Plaquanil
5	ICRC	54	31	Psoriatic arthritis	Joint pain, psoriasis	Yes	Yes	Methotrexate, Humira
6	ICRC	59	34	RA	Deformed joints	Yes	Yes	Prednisone, Methotrexate
7	ICRC	68	43	Scleroderma	Sclerodactyly, esophageal stenosis	Yes	Yes	Prednisone, Methotrexate
8	TMC	54	14	SLE	Butterfly rash	No	Yes	Methotrexate
9	BU	52	56	Psoriatic arthritis	Arthritis, rash, pericarditis, myopathy	Yes	Yes	Methotrexate

RA = rheumatoid arthritis; SLE = systemic lupus erythematosus; CVD = collagen vascular disease; UL = University of Louisville; MUSC = Medical University of South Carolina; ICRC = Ironrock Cancer and Research Center; TMC = Tanner Medical Center; BU = Brown University.

Table 3
Brachytherapy application and dosimetric characteristics

Characteristic	Number	Percent
Total no. of patients	9	100
Applicator type		
MammoSite	5	56
Contura	2	22
MammoSite ML	1	11
Multicatheter	1	11
Balloon volume (cc)[a]		
Median	45.5	
Range	35−100	
Skin distance (mm)[a]		
Median	7.5	
Range	3−30	
Total no. of catheters		
1	5	56
2−5	3	33
≥6	1	11
V_{100} (%)		
Median	95.6	
Range	88.1−100.0	
V_{150} (cc)		
Median	28.0	
Range	11.9−44.5	
V_{200} (cc)		
Median	5.3	
Range	3.1−9.8	

V_{100} = volume of target tissue receiving 100% of prescription dose; V_{150} = volume of target tissue receiving 150% of prescription dose; V_{200} = volume of target tissue receiving 200% of prescription dose.
[a] Applicable for balloon brachytherapy devices.

after the initiation of national and international clinical trials comparing mastectomy to BCT, case reports began to emerge in the medical literature urging caution in the application of BCT in women with CVD (2−4). During this early period of experience with BCT, authors described early and late toxicity in patients with RA, scleroderma, and SLE that were significantly more severe than that encountered in routine clinical practice. In some of these reports, patients were described as having intractable pain and fibrosis that necessitated mastectomy for resolution. These oft-cited anecdotal experiences filtered into Radiation Oncology and Surgery textbooks and heavily influenced clinical practice. Although pathophysiology remained poorly understood, CVD became generally considered as a relative or absolute contraindication to BCT approaches for women with early stage breast cancer and DCIS (11, 12).

Over time, significant efforts were undertaken to provide an evidence-based approach to the clinical challenge of managing patients with CVD. One of the first and largest single-institution retrospective reviews was reported by Morris and Powell (13) from the Massachusetts General Hospital. A total of 209 patients with documented CVD were reviewed and 263 sites of treatment were assessed. Approximately 10% of these irradiated sites exhibited

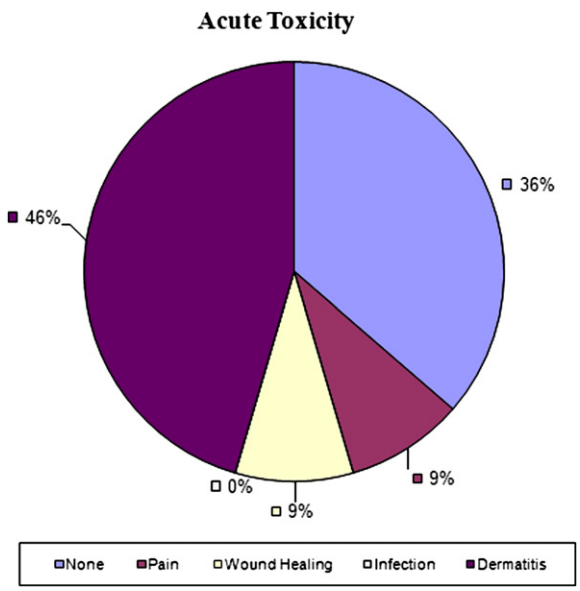

Fig. 1. Summary of acute toxicity for all the patients ($n = 9$). Acute toxicity was defined as sequelae that occurred on treatment or within 2 months of treatment completion. All toxicities were rated as Grade 1 or 2. There were no Grade 3 or higher toxicities.

higher than expected acute toxicity (≥Grade 3), and patients who experienced significant acute toxicity subsequently had a higher risk of late toxicity. These effects were most prevalent in patients with non-RA CVD. A specific retrospective analysis of irradiated patients with SLE was reported from the Mayo Clinic (14). For 21 patients with SLE who received 34 courses of external beam radiation therapy, the risk of acute late toxicity was found to be "moderate" and not significantly higher than expected. However, patients with more advanced lupus (renal involvement or more advanced American Rheumatism Association criteria) had a significantly increased risk for late toxicity.

In an endeavor to make meaningful comparisons of radiation-induced toxicity between patients with CVD and the general population, matched-pair analyses have since been carried out at several institutions. The first of these was reported by Ross *et al.* (15) at the University of Iowa, where a cohort of 39 patients with CVD that was matched to 61 controls showed no significant difference in acute or late complications in the entire group. On subgroup analysis, RA was associated with a slight increase in late complications and SLE was associated with a slight increase in acute reactions. At the University of Louisville, Phan *et al.* (16) reported that when 38 patients with CVD were matched with 38 controls, there was no significant difference in acute or late toxicity. Subgroup analysis showed a trend toward increased acute and late toxicity in patients with scleroderma.

The largest study to date was recently reported by Lin *et al.* (17) at the University of Michigan, where 73 patients with CVD (86 courses of radiotherapy) treated between 1985 and 2005 were matched to controls with respect to demographic information, site irradiated, and radiation therapy dose. This analysis showed no statistically significant difference in acute toxicity, but a statistically significant difference in late toxicity of any grade. There was a trend toward an increased severe late toxicity, which was especially significant for patients with scleroderma and SLE. The largest study specific to the breast cancer population was a matched-pair analysis of patients with CVD who underwent partial mastectomy and whole-breast radiotherapy at Yale University (18). Chen *et al.* reported that when a cohort of 36 patients with early stage breast cancer was matched in a 2 to 1 fashion to a control group, there was no significant difference in acute toxicity.

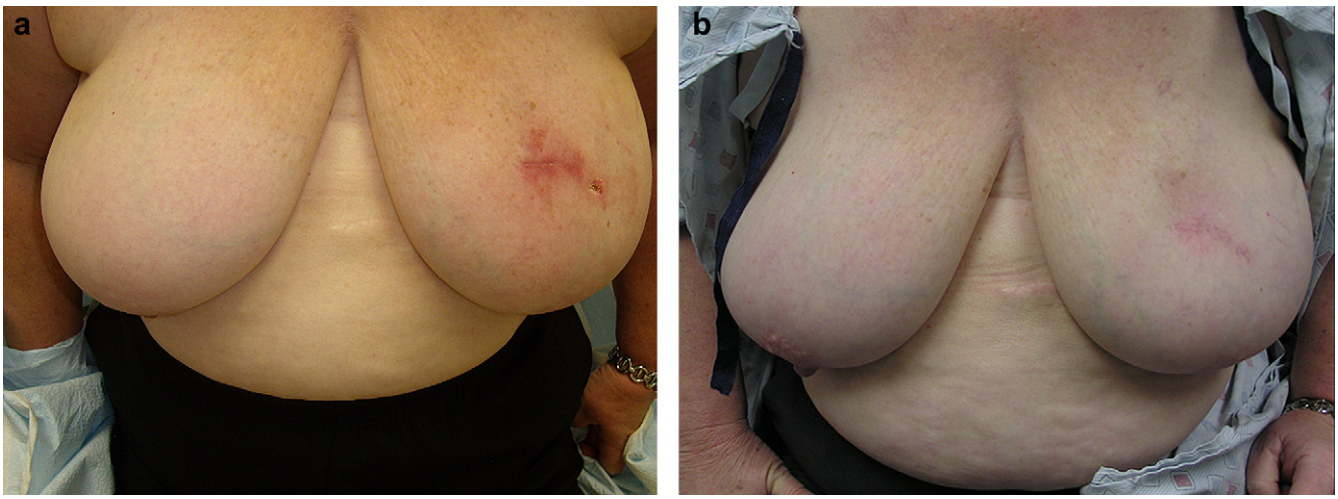

Fig. 2. Digital photographs of "Patient #1" (see Table 2). The patient was treated with multicatheter (Contura™) breast brachytherapy. The minimum balloon-to-skin distance was 5 mm. The patient was treated to a total dose of 34 Gy in 10 fractions. (a) Shows the patient's treated breast at 1 month posttreatment, with acute radiation dermatitis. (b) Shows the patient's treated breast at 7 months posttreatment, with mild hyperpigmentation.

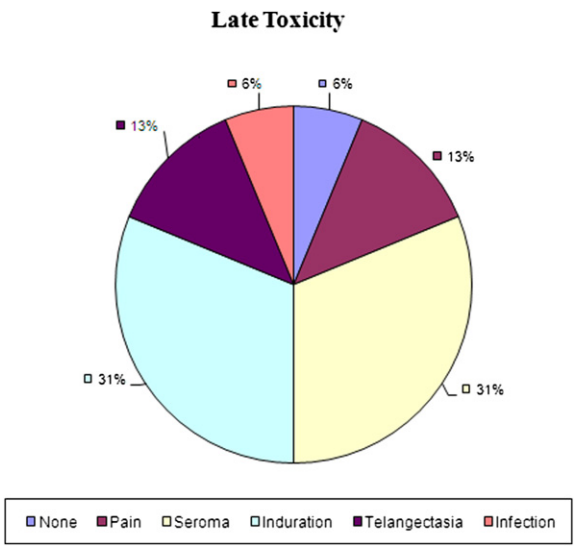

Fig. 3. Summary of late toxicity for all the patients ($n = 9$). Late toxicity was defined as sequelae that occurred more than 2 months from time of treatment completion. All toxicities were rated as Grade 1 or 2. There were no Grade 3 or higher toxicities.

Patients with scleroderma were found to have a statistically significant increase incidence in late radiation-induced toxicity.

All of the aforementioned studies focus on the experience and outcomes of CVD patients after external beam radiotherapy. At the time of this study, the only report in the medical literature of a patient with CVD treated with breast brachytherapy was reported in 1991 (4). A single patient with RA was treated with whole-breast radiotherapy to a total dose of 5251 cGy in 210 cGy per fraction with a subsequent 1600 cGy low-dose-rate interstitial ^{192}Ir boost. The patient had severe fibrosis, retraction, and breast pain that ultimately required a mastectomy for relief (4). Although the presence of RA in this patient is hypothesis generating, it is unclear as to whether the poor outcome in this patient was because of underlying CVD or simply the biologic effective dose of large external beam fraction sizes combined with a relatively high brachytherapy boost dose.

Over the last decade, the science of APBI has evolved and the strategy of breast brachytherapy has emerged as a popular alternative to whole-breast external beam radiotherapy for selected patients with early stage breast cancer (6). The most commonly reported toxicities are radiation dermatitis, infection/delayed wound healing, fat necrosis, and seroma (19−26). Our study is the first attempt to compile data on the subject of the use of definitive HDR brachytherapy in the adjuvant treatment of women with CVD who have elected for BCT. We present a collective experience with a wide variety of clinical presentations of CVD, with nearly 3 years median followup. Our numbers are small and, as with other reports, the studied CVD population is heterogeneous. However, the frequency and degree of toxicity, and cosmetic results described in this study are comparable to other modern series of multicatheter or balloon brachytherapy, with the most common acute and late toxicity of radiation dermatitis and seroma, respectively (7, 21, 25, 27).

Conclusions

Despite the growing body of evidence illustrating that CVD poses minimal increased risk with regard to radiation-induced side effects, patients with CVD are currently excluded from most clinical trials involving APBI (most notably, NSABP B-39/RTOG 0413) for breast cancer because of concerns regarding increased toxicity. Although more studies are needed to confirm these results, our experience shows that breast brachytherapy appears to be safe and well tolerated in this population. Therefore, it may not be necessary to exclude patients with CVD from future trials involving breast brachytherapy and other forms of APBI.

References

[1] Wo J, Taghian A. Radiotherapy in setting of collagen vascular disease. *Int J Radiat Oncol Biol Phys* 2007;69:1347−1353.
[2] Fleck R, McNeese MD, Ellerbroek NA, *et al*. Consequences of breast irradiation in patients with pre-existing collagen vascular diseases. *Int J Radiat Oncol Biol Phys* 1989;17:829−833.
[3] Varga J, Haustein UF, Creech RH, *et al*. Exaggerated radiation-induced fibrosis in patients with systemic sclerosis. *JAMA* 1991; 265:3292−3295.
[4] Robertson JM, Clarke DH, Pevzner MM, *et al*. Breast conservation therapy. Severe breast fibrosis after radiation therapy in patients with collagen vascular disease. *Cancer* 1991;68:502−508.
[5] Winchester DP, Cox JD. Standards for diagnosis and management of invasive breast carcinoma. American College of Radiology. American College of Surgeons. College of American Pathologists. Society of Surgical Oncology. *CA Cancer J Clin* 1998;48:83−107.
[6] Smith BD, Arthur DW, Buchholz TA, *et al*. Accelerated partial breast irradiation consensus statement from the American Society for Radiation Oncology (ASTRO). *Int J Radiat Oncol Biol Phys* 2009;74: 987−1001.
[7] Cuttino LW, Keisch M, Jenrette JM, *et al*. Multi-institutional experience using the MammoSite radiation therapy system in the treatment of early-stage breast cancer: 2-Year results. *Int J Radiat Oncol Biol Phys* 2008;71:107−114.
[8] Harper JL, Watkins JM, Zauls AJ, *et al*. Six-year experience: Long-term disease control outcomes for partial breast irradiation using MammoSite balloon brachytherapy. *Am J Surg* 2010;199:204−209.
[9] Israel PZ, Robbins AB, Shroff P, *et al*. Initial surgical experience evaluating early tolerance and toxicities in patients undergoing accelerated partial breast irradiation using the Contura Multi Lumen Balloon breast brachytherapy catheter. *Am Surg* 2009;75:1042−1049.
[10] Nelson JC, Beitsch PD, Vicini FA, *et al*. Four-year clinical update from the American Society of Breast Surgeons MammoSite brachytherapy trial. *Am J Surg* 2009;198:83−91.
[11] Perez CA. Principles and practice of radiation oncology. 4th ed. Philadelphia, PA: Lippincott Williams & Wilkins; 2004.
[12] Cox JD, Ang KK. Radiation oncology: rationale, technique, results. 8th ed. St. Louis, MO: Mosby; 2003.
[13] Morris MM, Powell SN. Irradiation in the setting of collagen vascular disease: Acute and late complications. *J Clin Oncol* 1997;15: 2728−2735.

[14] Pinn ME, Gold DG, Petersen IA, *et al*. Systemic lupus erythematosus, radiotherapy, and the risk of acute and chronic toxicity: The Mayo Clinic Experience. *Int J Radiat Oncol Biol Phys* 2008;71: 498−506.

[15] Ross JG, Hussey DH, Mayr NA, *et al*. Acute and late reactions to radiation therapy in patients with collagen vascular diseases. *Cancer* 1993;71:3744−3752.

[16] Phan C, Mindrum M, Silverman C, *et al*. Matched-control retrospective study of the acute and late complications in patients with collagen vascular diseases treated with radiation therapy. *Cancer J* 2003;9:461−466.

[17] Lin A, Abu-Isa E, Griffith KA, *et al*. Toxicity of radiotherapy in patients with collagen vascular disease. *Cancer* 2008;113:648−653.

[18] Chen AM, Obedian E, Haffty BG. Breast-conserving therapy in the setting of collagen vascular disease. *Cancer J* 2001;7:480−491.

[19] Harper JL, Jenrette JM, Vanek KN, *et al*. Acute complications of MammoSite brachytherapy: A single institution's initial clinical experience. *Int J Radiat Oncol Biol Phys* 2005;61:169−174.

[20] Belkacemi Y, Chauvet MP, Giard S, *et al*. Partial breast irradiation as sole therapy for low risk breast carcinoma: Early toxicity, cosmesis and quality of life results of a MammoSite brachytherapy phase II study. *Radiother Oncol* 2009;90:23−29.

[21] Keisch M, Vicini F, Beitsch P, *et al*. American Society of Breast Surgeons MammoSite Radiation Therapy System Registry Trial: Ductal carcinoma-in-situ subset analysis—4-year data in 194 treated lesions. *Am J Surg* 2009;198:505−507.

[22] Watkins JM, Harper JL, Dragun AE, *et al*. Incidence and prognostic factors for seroma development after MammoSite breast brachytherapy. *Brachytherapy* 2008;7:305−309.

[23] Evans SB, Kaufman SA, Price LL, *et al*. Persistent seroma after intraoperative placement of MammoSite for accelerated partial breast irradiation: Incidence, pathologic anatomy, and contributing factors. *Int J Radiat Oncol Biol Phys* 2006;65:333−339.

[24] Niehoff P, Ballardini B, Polgar C, *et al*. Early European experience with the MammoSite radiation therapy system for partial breast brachytherapy following breast conservation operation in low-risk breast cancer. *Breast* 2006;15:319−325.

[25] Benitez PR, Keisch ME, Vicini F, *et al*. Five-year results: The initial clinical trial of MammoSite balloon brachytherapy for partial breast irradiation in early-stage breast cancer. *Am J Surg* 2007;194:456−462.

[26] Ravi A, Lee S, Karsif K, *et al*. Intraoperative placement of MammoSite for breast brachytherapy treatment and seroma incidence. *Brachytherapy* 2010;9:76−80.

[27] Vicini F, Beitsch PD, Quiet CA, *et al*. Three-year analysis of treatment efficacy, cosmesis, and toxicity by the American Society of Breast Surgeons MammoSite Breast Brachytherapy Registry Trial in patients treated with accelerated partial breast irradiation (APBI). *Cancer* 2008;112:758−766.